

## Oral Manifestations in Angelman Syndrome: A Systematic Review of the Dental Literature.

José González-Serrano<sup>1</sup>, Víctor Manuel Paredes-Rodríguez<sup>1</sup>,  
Carlos González-Serrano<sup>2</sup>, Gema Torrijos Gómez<sup>3</sup>, Jorge A. Cano-Durán<sup>1</sup>,  
Rosa María López-Pintor<sup>1</sup>, Gonzalo Hernández Vallejo<sup>1</sup>.

<sup>1</sup> Department of Oral Medicine and Orofacial Surgery. Faculty of Odontology. Complutense University. Madrid, Spain.

<sup>2</sup> Rey Juan Carlos University, Alcorcón, Madrid. Spain.

<sup>3</sup> Faculty of Odontology. Complutense University. Madrid, Spain.

---

### Abstract:

**Background.** Angelman syndrome (AS) is a genetic disease whose incidence varies from one in 10.000 to one in 40.000 newborns. Clinically, it is characterized by a severe growth delay, speech alterations, ataxia, craniofacial abnormalities and strange behaviors. The aim of this paper is to provide a systematic review of the literature regarding the oral manifestations of this uncommon disease.

**Material and methods.** A literature search in PubMed/MEDLINE without date restriction until May 10th, 2016 was performed.

**Results.** Five papers met the inclusion criteria describing a total of 14 cases with AS (the first corresponds to the year 2008 and the last in 2013). Some of the dental problems among these patients such as prognathism, diastemas, lingual protrusion or drooling are common and are included as associated criteria for the diagnosis of the syndrome.

**Conclusions.** The anterior open bite is also a very common oral finding and could be also considered as an associated criterion.

**Keywords** – Angelman syndrome, oral manifestations, systematic review.

---

### I. Introduction

Angelman syndrome (AS) was first described by Dr. Harry Angelman in 1965 [1]. It is a rare genetic disorder characterized by severe delay in growth, speech alterations, ataxia, craniofacial abnormalities and strange behaviors accompanied by a state of happiness and occasional outbreaks of laughter [2,3]. There is not an established prevalence with regard to sex, and its estimated incidence oscillates between 1/10.000 and 1/40.000 newborns [4]. Its etiology is related to genetic factors as a deletion of maternal chromosome 15q11-q13 and UBE3A gene mutation [5]. Moreover, we should know that, 15q11-q13 gene deletion of the paternal chromosome brings about Prader-Willi syndrome [6].

More than the 80% of these patients suffer from epileptic attacks [7], and that is the reason why the pharmacological treatment is focused on controlling those attacks. The effectiveness seems to be higher with valproic acid and clonazepam. On the other hand, it appears to be lower with phenobarbital and carbamazepine [8]. Furthermore, these patients are characterized by the presence of sleep disorders that, in some cases, could be treated pharmacologically [9].

It is difficult to achieve an early diagnosis since there is no specific manifestation in newborns. However, there are distinctive clinical findings which are widely accepted as diagnostic criteria of AS [7] (Table 1). Despite the fact that it is a cureless disease, different therapies are used, focused on behavior and neurologic improvement [10,11].

Since the incidence of this disease is low, there is no consensus about the most common oral manifestations in these patients, whose diagnosis would be helpful to an early diagnose of the disease. Similarly, recognize these oral lesions could help to establish a dental protocol for detection and treatment of early dental abnormalities in patients with AS. The aim of the present study is to provide a systematic review of the literature on oral manifestations of this rare disease.

### II. Material and Methods

#### Search strategy

A literature search using Pubmed/MEDLINE database without date restriction (until May 10th, 2016) was performed. The following keywords were used: (“Angelman syndrome”) AND ((dental OR oral) AND (manifestations OR findings)) (Figure 1). The articles were independently assessed by two reviewers (JG-S,

VMPR). Moreover, to ensure completeness of the systematic review, an additional hand search to find potential eligible studies was performed and all the references in the articles deemed eligible for inclusion in the study were searched.

#### **Study selection**

- **Inclusion criteria.** Full-text articles were included regardless of time period of study and year of publication if they met the following inclusion criteria: (1) articles in English (2) that present oral manifestations in case (at least) with Angelman syndrome and (3) describe oral and/or dental characteristics of the disorder and the treatment used.
- **Exclusion criteria.** Studies excluded were: (1) those published in other language than English and (2) those studies that did not present the oral/dental treatment.

#### **Data collection and extraction**

Two independent researchers (JG-S and VMPR) compared search results to ensure completeness. Those articles not meeting study eligibility criteria (only in English) were removed. Then the reviewers screened full title and abstracts of the remaining papers individually. Differences in eligible studies were resolved by discussion with a third reviewer (CG-S). They went on to obtain the full papers for all potentially eligible studies, which were then checked for eligibility using the standard abstraction forms characteristics: first authors, year of publication, number and years of cases and oral manifestations (Table 2). The eligible papers were then included in the systematic review.

### **III. Results**

Of the 31 articles found, only five met the search requirements (Figure 1). Studies published up-to-date regarding oral manifestations of AS, 3 jobs included a single case report and two articles included two case series, with 8 and 3 patients respectively (Table 2). In the revised dental literature, only 14 people with this rare syndrome were subjected to an oral examination. The mean age of the patients described in this review was almost 16 years (exactly 15.7 years, taking as 11 years for Murakami et al. case, when it started treatment) [12], being the age range between 3 and 21 years.

The first article published in the dental literature is that of Murakami et al. (2008) [12]. The clinical case of a male followed from 4 to 15 years of age was described. He came to the dental office at the age of 11 due to an interincisal diastema. A frenulectomy was performed to eliminate the low insertion of the labial frenulum, in order to close the diastema. Afterwards, he was treated with orthodontics, as his parents demanded it. The complete closure of the diastema was achieved at 5 months, and simultaneously he received topical fluoride applications in his regular visits. When the diastema was completely closed, a palatal retainer was placed. When he was 12 years old, first permanent molars were sealed with composite resin. At the age of 13, his second permanent molars did not erupt, and after 3 months follow up without change, an ulectomy was performed. Two years later, at the age of 15, he only needed regular check-ups where either prophylactic treatments or fluoride-containing varnish were implemented. Different types of behavior management techniques as 'say-show-do', nonverbal communication, voice control or positive feedback were required. The use of cheek retractors and physical restriction were essential to control involuntary movements of head and extremities.

Ramanathan et al. (2008) [13] reported a clinical case of a 5 year-old male who came to the dental office due to excessive drooling. He was surgically intervened to restore the submandibular canal. The procedure was performed under general anesthesia, and it lasted 2 hours approximately. During the post-operative period, there were no added complications, and the patient got medically discharged in 2 days.

Three years later, Sarkar et al. (2011) [14] reported a clinical case of a 6 year-old female who arrived at the dental office presenting wide carious lesions located in the upper-front teeth. Glass ionomer restorations were performed, fluoride toothpastes were prescribed, instructions on hygiene and brushing techniques were given, and regular preventive programs were planned. Initially, it was decided to do everything under sedation or general anesthesia. However, the anesthesiologist dismissed the idea since the procedure would be contraindicated due to recent epileptic episodes. Therefore, it was decided to carry out the treatment with the help of physical restraint.

Gallo et al. (2012) [15] described the largest series of cases collected, with 8 patients (mean 6.8 years). They were 5 women and 3 men who came, most of them, presenting dental pain accompanied by infection, drooling, sleeping disorders and worsening anxiety. The anamnesis revealed difficulties in maintaining good oral hygiene, and frequent consumption of sugary drinks that originated in injuries that required urgent dental treatment. General anesthesia was necessary to treat 5 of the 8 patients for lack of cooperation on their behalf. The dental treatment performed was: extraction of deciduous and permanent teeth, composite resin restorations and prophylaxis. There were no intraoperative complications, and in 2 of the patients bronchospasm occurred in

the postoperative period, which were resolved with cortisone. The 3 remaining patients were controlled with regular routine visits. They were also instructed in performing myofunctional exercises; thus strengthening the orbicular muscles of the lips to counteract tongue thrusting between upper and lower jaw, open bite, and to be able to contain saliva.

Finally, de Queiroz et al. (2013) [16] presented a series of cases with 3 patients (mean age 12 years) who consulted on the need for dental treatment. The first was a 21 year-old male, who was treated with a dental prophylaxis followed by topical application of fluoride for 3 minutes. Subsequently, pit and fissure sealants were applied on all premolars and molars with deep pits and fissures as a preventive treatment, due to the high risk of caries of the patient. The second case was a 12 year-old girl who received instructions on oral hygiene techniques and dietary advice. It took 4 sessions of dental prophylaxis with applications of chlorhexidine digluconate (0.12%) and topical fluoride for 3 minutes. Afterwards, 4 periapical radiographs were taken, one in each posterior region, and it was decided to extract the 4 first primary molars to be extensively destroyed by decay and because the first premolars had the final 2/3 of the root already formed. The 4 first permanent molars were restored with composite resin. The third and final case was a 3 year-old girl who received oral hygiene instructions and dietary advice. A dental prophylaxis and the application of topical fluoride was performed, the second primary molars which presented hypoplastic areas previously confirmed with periapical radiographs were restored with composite resin, and in the first primary molars sealants of pits and fissures were applied after confirming the absence of caries radiographically. In the 3 cases, the treatments were performed with behavior management techniques as 'tell-show-do', nonverbal communication or positive reinforcement. Finally, the use of physical restraint and a mouth gag were needed for all procedures. All reconstructive procedures were performed under local anesthesia, and absolute isolation with rubber dam. The 3 patients followed a program of monitoring every 4 months for two years, receiving prophylaxis and topical fluoride applications to control the plaque. After this period, the patients returned once a year for a clinical and radiographic follow-up.

#### **IV. Discussion**

The small sample found in this review (14 patients) could be explained due to the fact that, AS is a rare disorder with an estimated prevalence between 1/10.000 and 1/40.000 newborns [4]. These facts could limit the extraction of solid conclusions as regards to oral pathology grade and the problems originated by these patients in the dental management.

A good medical history which registers all the drugs taken by these patients for the control of the illness has a huge importance, since 80% of them are epileptic [3]. Oral findings derived from anticonvulsant drugs could generate xerostomia, stomatitis, glossitis, multiforme erythema, dysgeusia, gingival overgrowth, etc. [16]; consequences which would be difficult to evaluate because of the mental problems and the lack of speech that AS patients have, could even mask the presence of pain.

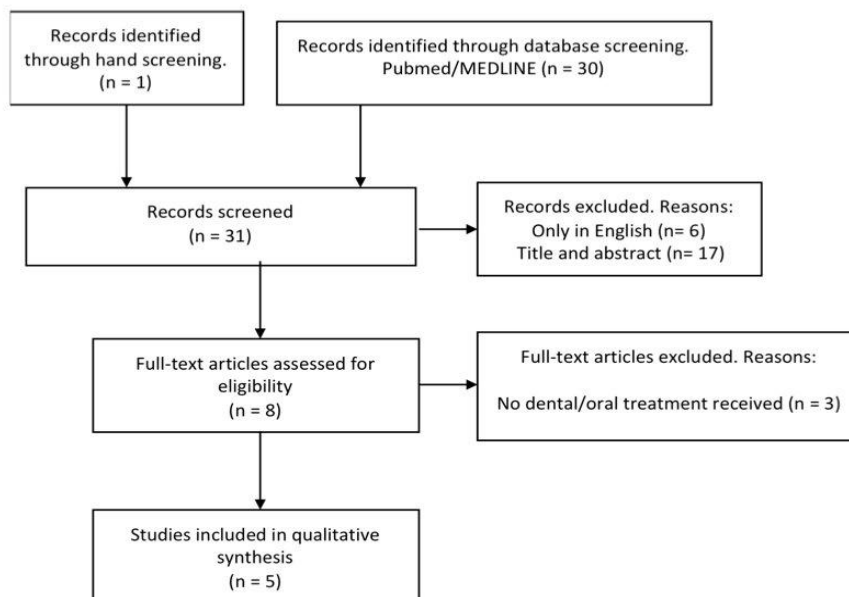
Regarding orofacial appearances found in the literature, which comes from the specific conditions of the syndrome, are described in Table 2. Despite the fact that these oral findings are not exclusive of this syndrome, as they could be also found in other diseases characterized by the presence of oral habits or seizures. Nonetheless, there are some features, as prognathism, diastemas, lingual protrusion, drooling, eruptive alterations and anterior open bite; which appear to be more frequent in AS [12,15]. In any case, all the authors agree on the necessity of early dental visits [15]. Murakami, et al. [12] mention that they should return periodically every 4 months, so that the AS patients can familiarize with the dentist and can be informed about different oral hygiene techniques and eating habits to prevent dental pathology and improve, thus, the quality of life of these patients [15].

Drooling seems more likely due to a lack of swallowing rather than excessive secretion, although sometimes excessive salivation is caused by stomatitis or the use of some medications. Myofunctional exercises, such as the interposition of a button attached to dental floss in the buccal vestibule, are used to strengthen the orbicular oris muscles to contrast tongue interposition between the jaws, anterior open bite and contain saliva [15]. As if it were any other child, dental treatment in these patients should be approached from a good behavior management [16]. The used techniques should always be adapted to each individual case, taking into account the communicative limitations of the patient, mental retardation or involuntary movements made by these patients [16]. Firstly, we should try behavioral management techniques such as 'tell-show-do' nonverbal communication or positive reinforcement [15]. If not sufficient, physical restraint [12,14,16] and the mouth gag [12-16] should be used. As a last choice, some authors have used general anesthesia due to the lack of cooperation for a proper dental treatment [13,15].

## V. Figures and Tables

Pubmed/MEDLINE search without date restriction until May 10<sup>th</sup>, 2016:

("Angelman syndrome") AND ((dental OR oral) AND (manifestations OR findings))



**Figure 1.** Flow diagram of the literature search.

<p>A. Consistent (100%)</p> <ul style="list-style-type: none"> <li>• Developmental delay, functionally severe.</li> <li>• Movement or balance disorder, usually ataxia of gait, and/or tremulous movement of limbs. Movement disorder can be mild. May not appear as frank ataxia but can be forward lurching, unsteadiness, clumsiness, or quick, jerky motions.</li> <li>• Behavioral uniqueness: any combination of frequent laughter/smiling; apparent happy demeanor; easily excitable personality, often with uplifted hand-flapping, or waving movements; hypermotoric behavior.</li> <li>• Speech impairment, none or minimal use of words; receptive and non-verbal communication skills higher than verbal ones.</li> </ul>
<p>B. Frequent (more than 80%)</p> <ul style="list-style-type: none"> <li>• Delayed, disproportionate growth in head circumference, usually resulting in microcephaly (<math>\leq 2</math> SD of normal OFC) by age 2 years. Microcephaly is more pronounced in those with 15q11.2-q13 deletions.</li> <li>• Seizures, onset usually &lt;3 years of age. Seizure severity usually decreases with age but the seizure disorder lasts throughout adulthood.</li> <li>• Abnormal EEG, with a characteristic pattern, as mentioned in the text. The EEG abnormalities can occur in the first 2 years of life and can precede clinical features, and are often not correlated to clinical seizure events.</li> </ul>
<p>C. Associated (20%–80%)</p> <ul style="list-style-type: none"> <li>• Flat occiput.</li> <li>• Occipital groove.</li> <li>• Protruding tongue.</li> <li>• Tongue thrusting; suck/swallowing disorders.</li> <li>• Feeding problems and/or truncal hypotonia during infancy.</li> <li>• Prognathia.</li> <li>• Wide mouth, wide-spaced teeth.</li> <li>• Frequent drooling.</li> <li>• Excessive chewing/mouthing behaviors.</li> <li>• Strabismus.</li> <li>• Hypopigmented skin, light hair, and eye color compared to family), seen only in deletion cases.</li> <li>• Hyperactive lower extremity deep tendon reflexes.</li> <li>• Uplifted, flexed arm position especially during ambulation.</li> <li>• Wide-based gait with pronated or valgus-positioned ankles.</li> <li>• Increased sensitivity to heat.</li> <li>• Abnormal sleep-wake cycles and diminished need for sleep.</li> <li>• Attraction to/fascination with water; fascination with crinkly items such as papers and plastics.</li> <li>• Abnormal food related behaviors.</li> <li>• Obesity (in the older child).</li> <li>• Scoliosis.</li> <li>• Constipation.</li> </ul>

SD: standard deviations; OFC: occipitofrontal circumference; EEG: electroencephalogram.

Table 1. Diagnostic criteria for Angelman syndrome [7].

Authors	Year	Cases (n)	Age (years)	Oral manifestations
Murakami, et al [12]	2008	1	From 4 to 15	Habit of pacifier sucking, open bite, prominent diastema between the central incisors and eruption delays.
Ramanathan, et al [13]	2008	1	5	High arched palate, poor oral motor control, difficulty controlling his saliva, blowing/sucking and with mouth closure.
Sarkar, et al [14]	2011	1	6	Caries in upper incisors and in temporary molars, heavy plaque and stain deposits indicate poor oral hygiene.
Gallo, et al [15]	2012	8	Average 6.8	Wide mouth and jaws, diastemas, insertion of the tip of the tongue between the front teeth and front open bite, frequent drooling, sucking, eating and drinking difficulties, enamel erosions, incipient tooth lesions, disturbances in tooth eruption, mandibular prognathism with anterior cross bite and deep dental caries on primary molars.
de Queiroz et al [16]	2013	3	Average 12	Prominent mandible (prognathia), large mouth, widely spaced teeth, thin upper lip, tongue protrusion, excessive chewing behavior, excessive drooling, enhanced cheeks, mouth breathing, long and narrow face, open mouth, lowered mandible position, disproportion of facial thirds and hypotonia of tongue and lips.

**Table 2.** Oral manifestations of Angelman syndrome found in the dental literature.

## VI. Conclusion

In conclusion, this review shows that AS most representative oral manifestations are: prognathism, presence of diastemas, lingual protrusion and drooling, which are considered as associated criteria for the diagnosis of this syndrome. Furthermore, the anterior open bite is also a very common oral finding and could be also considered as a new associated criterion for the diagnosis of AS.

## Acknowledgements

There are no acknowledgements.

## References

- [1] Hart H. 'Puppet' children. A report on three cases (1965). *Dev Med Child Neurol.* 2008; 50: 564.
- [2] Dagli A, Buiting K, Williams CA. Molecular and Clinical Aspects of Angelman Syndrome. *Mol Syndromol.* 2012; 2: 100-12.
- [3] Bird LM. Angelman syndrome: review of clinical and molecular aspects. *Appl Clin Genet.* 2014; 7: 93-104.
- [4] Duca DG, Craiu D, Boer M, Chiriac SM, Arghir A, Tutulan-Cunita A, et al. Diagnostic approach of angelman syndrome. *Maedica (Buchar).* 2013; 8: 321-7.
- [5] Chamberlain SJ, Lalande M. Angelman syndrome, a genomic imprinting disorder of the brain. *J Neurosci.* 2010; 30: 9958-63.
- [6] Cruvinel E, Budinetz T, Germain N, Chamberlain S, Lalande M, Martins-Taylor K. Reactivation of Maternal SNORD116 Cluster via SETDB1 knockdown in Prader-Willi Syndrome iPSCs. *Hum Mol Genet.* 2014; 23: 4674-85.
- [7] Williams CA, Beaudet AL, Clayton-Smith J, Knoll JH, Kyllerman M, Laan LA, et al. Angelman syndrome 2005: updated consensus for diagnostic criteria. *Am J Med Genet A.* 2006; 140: 413-8.
- [8] Thibert RL, Conant KD, Braun EK, Bruno P, Said RR, Nespeca MP, et al. Epilepsy in Angelman syndrome: a questionnaire-based assessment of the natural history and current treatment options. *Epilepsia.* 2009; 50: 2369-76.
- [9] Pelc K, Cheron G, Boyd SG, Dan B. Are there distinctive sleep problems in Angelman syndrome? *Sleep Med.* 2008; 9: 434-41.
- [10] Allen KD, Kuhn BR, DeHaai KA, Wallace DP. Evaluation of a behavioral treatment package to reduce sleep problems in children with Angelman Syndrome. *Res Dev Disabil.* 2013; 34: 676-86.
- [11] Heald M, Allen D, Villa D, Oliver C. Discrimination training reduces high rate social approach behaviors in Angelman syndrome: proof of principle. *Res Dev Disabil.* 2013; 34: 1794-803.
- [12] Murakami C, Nahas Pires Correa MS, Nahas Pires Correa F, Nahas Pires Correa JP. Dental treatment of children with Angelman syndrome: a case report. *Spec Care Dentist.* 2008; 28: 8-11.
- [13] Ramanathan KR, Muthuswamy D, Jenkins BJ. Anaesthesia for Angelman syndrome. *Anaesthesia.* 2008; 63: 659-61.
- [14] Sarkar PA, Shigli A, Patidar C. Happy Puppet syndrome. *BMJ Case Rep.* 2011; 10.
- [15] Gallo C, Marcato A, Beghetto M, Stellini E. Dental treatment in Angelman syndrome patients. 8 case reports. *Eur J Paediatr Dent.* 2012; 13: 345-8.
- [16] de Queiroz AM, de Siqueira Melara T, Fernandes Ferreira PD, Lucisano MP, De Rossi A, Nelson-Filho P, et al. Dental findings and special care in patients with Angelman syndrome: a report of three cases. *Spec Care Dentist.* 2013; 33: 40-5.