

Prospective, Multicenter Evaluation of Trabecular Metal-Enhanced Titanium Dental Implants Placed in Routine Dental Practices: 1-Year Interim Report From the Development Period (2010 to 2011)

Markus Schlee, DDS;* Guillermo Pradies, DDS;†‡ Wolf-Ullrich Mehmke, DDS;§ Arnaud Beneytout, DDS;¶ Matthais Stamm, DDS;** Ramón Gómez Meda, DDS;†† Torsten Kamm, DDS;‡‡ Francois Poiroux, DDS;§§ Franz Weinlich, DDS;¶¶ Mariano del Canto Pingarron, DDS;*** Eric Crichton, DDS;††† Jean-Baptiste Poulet, DDS;‡‡‡ Philippe Bousquet, DMD§§§

ABSTRACT

Background: A prospective, multicenter study is currently evaluating a novel titanium implant with a highly porous tantalum midsection (tantalum material [TM]) placed in an uncontrolled patient population.

Purpose: Interim 1-year results from the development period (2010–2011) are reported.

Materials and Methods: Investigators in 22 clinical sites located in five European countries randomly selected and treated partially edentulous patients in accordance with the implant's instructions for use and the investigators' professional judgments. Oversight was provided by the local institutional review boards. Subjects were treated with 1 to 2 TM dental implants in maxillary or mandibular location(s).

Results: To date, 105 patients with 57 maxillary and 88 mandibular implants have completed 1 year of clinical monitoring. Within this interim group, 28 patients had concomitant health conditions that may elevate risks for long-term crestal bone loss and/or implant survival. Three implants failed due to local or systemic infection, and four implants failed to integrate. Cumulative implant survival was 95.2% ($n = 138/145$) with 0.43 ± 0.57 mm of mean marginal bone loss in this interim group.

Conclusion: TM dental implants were clinically effective under various clinical conditions in an uncontrolled patient population with and without concomitant health conditions.

KEY WORDS: osseoincorporation, titanium–tantalum implant, trabecular metal

*Private Practice in Periodontology and Oral Implantology, Forchheim, Germany; †Professor and Head, Faculty of Dentistry, Complutense University, Madrid, Spain; ‡Private Practice in Prosthodontics and Oral Implantology, Madrid, Spain; §Private Practice in Periodontology and Oral Implantology, Chemnitz, Germany; ¶Private Practice in Oral Surgery, Periodontology, and Oral Implantology, Bordeaux, France; **Private Practice in Oral Implantology and Periodontology, Overath, Germany; ††Private Practice in Oral Surgery, Ponferrada, Leon, Spain; ‡‡Private Practice in Esthetic Dentistry, Periodontology, and Oral Implantology, Baden-Baden, Germany; §§Private Practice in Periodontology and Oral Implantology, La Rochelle, France; ¶¶Private Practice in General Dentistry and Oral Implantology, Neu-Isenburg, Germany; ***Professor and Director, Oral Surgery, Implantology and Periodontology, University of León, Leon, Spain; †††Private Practice in Periodontology and Oral Implantology, Houilles, France; ‡‡‡Private Practice in Oral Implantology, Tarare, France; §§§Professor, Periodontology and Implantology, Montpellier University, Béziers, France

INTRODUCTION

The phenomenon of bone fusing to titanium implants was first discovered by Bothe and colleagues¹ in 1940 and was reported again in 1951 by Leventhal.² In 1977, Branemark and colleagues³ scientifically documented

Corresponding Author: Dr. Markus Schlee, Bayreuther Strasse 39, D-91301 Forchheim, Germany; e-mail: markus.schlee@32schoenezaehne.de

© 2014 The Authors. Clinical Implant Dentistry and Related Research Published by Wiley Periodicals, Inc.

This is an open access article under the terms of the Creative Commons Attribution License, which permits use, distribution and reproduction in any medium, provided the original work is properly cited.

DOI 10.1111/cid.12232

the methods for predictably achieving and maintaining bone fusion to titanium implants through a process they called *osseointegration*. Actual bone attachment to an osseointegrated implant has been estimated to typically range from 50% to 80% of the surface.^{4,5} A variety of factors, such as the character of the implant surface and the nature of the surrounding tissues, can influence the overall percentage of bone attachment.^{6–8} Various modifications to dental implant surfaces, such as grit-blasting, acid-etching, coating, or a combination of procedures, have been introduced over the past three decades in an attempt to increase the overall percentage of bone attachment.^{9–11} In orthopedic medicine, research has also focused on development of porous implant coatings to mechanically supplement osseointegration through additional bone ingrowth into the implant surface.^{12,13} Numerous studies^{10–12} since the 1970s have reported that a coating's pore size and porosity are determining factors for successful bone ingrowth. For example, researchers found that while a pore size of 100 μm would be generally acceptable for bone ingrowth,¹⁴ pores 150 μm would be needed for osteon formation inside a porous material,¹⁵ and pores more than 300 μm in size would be required to support potential ingrowth of both bone and vascular structures.¹⁶

Because pore sizes tended to be irregular and porosity extremely limited in applied surface coatings, orthopedic researchers used a biomimetic approach in developing a highly porous, tantalum material (TM) (Trabecular Metal™ Material, Zimmer TMT, Parsippany, NJ), which simulates the structure and more closely approximates the elasticity of trabecular bone than titanium and other major surgical metals.^{17–25} The porous material is fabricated by coating a vitreous carbon skeleton with elemental tantalum through a chemical vapor deposition process.^{17,18,20} The final material provides up to 75% to 80% porosity through a network of interconnected pores (size = $\sim 440 \mu\text{m}$) and dodecahedron-shaped cells (size = $\sim 540 \mu\text{m}$) in regular sizes and shapes.^{20–22,25} The high degree of porosity has been reported to support the formation of bone and vascular structures inside the material.^{18,19,21,23,24,26} Since 1997, this porous TM has been used extensively in orthopedic hip, knee, and spine implants to supplement anchorage through a combination of bone ingrowth and bone ongrowth,^{19–21,23–26} which has been termed *osseoincorporation*.²⁷

Based on its extensive clinical use in orthopedics, dental researchers modified a conventional tapered, multithreaded, root-form, titanium dental implant design by replacing the threads in the midsection of the implant body with an unthreaded sleeve of the highly porous TM (Figure 1).²⁷ The cervical, apical, and internal implant structures are made of titanium alloy (Ti-6Al-4V grade 5) with a microtextured surface.^{27,28} The cervical region of the implant includes a series of radial microgrooves and surface microtexture that either extends to the top of the implant or optionally ends below a 0.5-mm-wide section of machined titanium surface (Figure 1).

Unlike cervical microthreads, radial microgrooves feature a “scalloped” or “barbed” geometry. The microgrooves slope coronally at a 15- to 21-degree angle, range from 50.8 to 76.2 μm in depth depending on the area of slope, and are 279.4 μm in vertical height (base to top of groove). In a series of in vitro and in vivo cellular studies, Chehroudi and colleagues^{29,30} reported that horizontal microgrooves were effective in impeding epithelial downgrowth. In a later study, Chehroudi and colleagues³¹ found that fibroblast cells blocked epithelial downgrowth by inserting into horizontal microgrooves




Figure 1 The study implant (A) is a tapered design with a midsection of highly porous trabecular metal material. Its cervical section is manufactured with microgrooves, surface microtexturing either below a 0.5-mm-wide machined surface (B) or fully textured to the top of the implant (C).

that were $\geq 10 \mu\text{m}$ deep. At the histologic level, Hall and colleagues³² reported that microgrooves 110 to 200 μm wide and 70 μm deep stimulated bone to preferentially form within and along the microgrooves in the rabbit model and that grooves 110 μm in width significantly increased resistance to shear forces. The researchers concluded that such microgrooves may be one way to optimize implant stability in suboptimal clinical conditions.³² The present microgroove design is thus intended to facilitate osseointegration via crestal bone growth into microgrooves, and the sloped geometry is designed to discourage plaque accumulation and/or bacterial colonization in the event of exposure to the intrasulcular or intraoral environments. The radial microgrooves are positioned 635 μm below the top of the implant to preserve the mechanical strength of the implant's prosthetic platform.

Extending cervical microtexture to the top of the implant in the canine model has also been reported to reduce the amount of peri-implant crestal bone loss without adversely affecting soft tissue health; however, concern about the possibility of increased bacterial attachment to microtextured implant surfaces as compared with machined (turned) surfaces exposed to the gingival crevice in humans has been expressed in the dental literature.³³ After 6 months of plaque accumulation in dogs, the roughened surfaces of acid-etched implants, which have been previously reported²⁸ to be slightly rougher ($R_a = 803 \pm 257 \text{ nm}$) than the present microtextured surface ($R_a 756 \pm 73 \text{ nm}$), failed to influence any greater plaque formation or establishment of inflammatory cell lesions in the peri-implant mucosa than control implants with machined surfaces.³⁴ Based on these findings, cervical microgrooves and surface microtexture were incorporated into the cervical sections of TM dental implants. For patients who may have an elevated risk of crestal bone loss, such as smokers or patients with a history of periodontal disease, a 0.5-mm-high machined surface option is available for clinicians who may still be concerned about potential exposure of the microtextured surface (Figure 1). The biocompatibility and corrosion resistance of all three materials (titanium, tantalum, vitreous carbon) used in the implant design have been extensively documented^{35–37} and clinically demonstrated over more than 15 years of use in orthopedic implants. Preliminary research³⁸ has found that TM dental implants were clinically effective when immediately provisionalized out of occlusion within 24

hours of implant placement and definitively restored in occlusion within 14 days of placement in a controlled patient population. There is a little documentation, however, on the clinical functioning of TM dental implants placed in an uncontrolled patient population encountered in routine dental practices.

This article reports on the 1-year interim results of a nonrandomized, noninterventional, prospective, multicenter evaluation of TM dental implants placed in an uncontrolled population during the implant development period of 2010 to 2011.

MATERIALS AND METHODS

The objective of this 5-year noninterventional study was to evaluate the functioning of TM dental implants in a cross section of patients that clinicians would routinely treat in their practices. Noninterventional studies are designed to help avoid manufacturer bias by allowing products to be used as they would be in normal dental practices. Results are systematically documented and analyzed to determine statistically significant outcomes. A longitudinal data collection program (LDCP) was established to monitor the study and provide investigators with a secure method of data collection through digital case report forms housed in a password-protected database. Patient selection and case planning were left to the professional judgment of the investigators, all of whom had years of experience in placing multiple implant systems. Treatment was limited, however, to two study implants per patient, and no study device could be placed adjacent to another dental implant. This study complies with the declaration of Helsinki and Good Clinical Practice guidelines and is being conducted under the auspices of the local institutional review boards. The 22 study centers are located in Germany, Italy, the Netherlands, Spain, and France. A total of 268 subjects have been enrolled in the LDCP to date and treated per protocol with 377 TM dental implants (reference group). This interim report covers a subgroup of all subjects whose implants were placed during the implant development period from October 2010 to June 2011 and who have completed 1 year of clinical monitoring after implant placement (focus group).

Patient Selection and Evaluation

To help ensure clinical safety and study compliance, patients were required to meet minimal selection

TABLE 1 Patient Selection Criteria

Inclusion	At least 18 years of age Partially dentate with missing molar(s) or premolar(s) In need of implant therapy to replace one or more missing posterior teeth
Exclusion	Preexisting implant adjacent to the proposed study treatment site Pregnancy Lactating mothers

criteria (Table 1). After discussing the treatment plan, alternative options, and answers to patient questions, each subject provided signed informed consent prior to implant treatment.

Preliminary patient evaluations included careful review of medical and dental histories, clinical and radiographic examinations, evaluation of oral hygiene, and assessment of the patient's ability to commit to study procedures and clinical monitoring. A diagnostic workup was performed to assess the volume and location of available bone and the esthetic and functional needs of the patient. Working casts were fabricated to determine the jaw relationships, available occlusal dimension, proposed implant position(s), crown/root ratio(s), and potential complications. This allowed the fabrication of a prosthetic wax-up and surgical template to guide placement of the implants relative to the planned prosthesis.

Treatment

Case planning and surgical procedures were left to the professional judgment of each investigator in

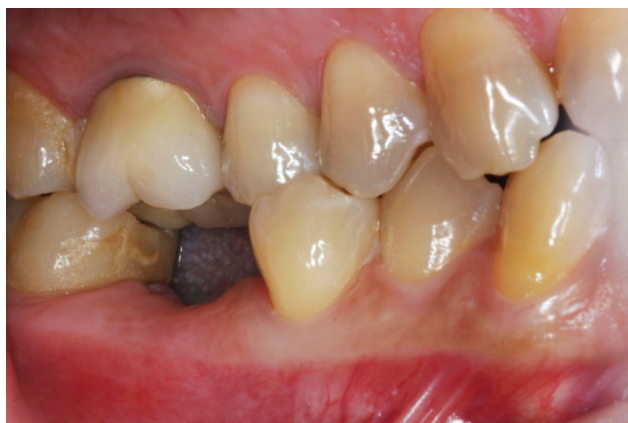

Figure 2 A 43-year-old female presented with a missing mandibular left molar and a thick, soft tissue biotype (contributed by Guillermo Pradies, DDS).

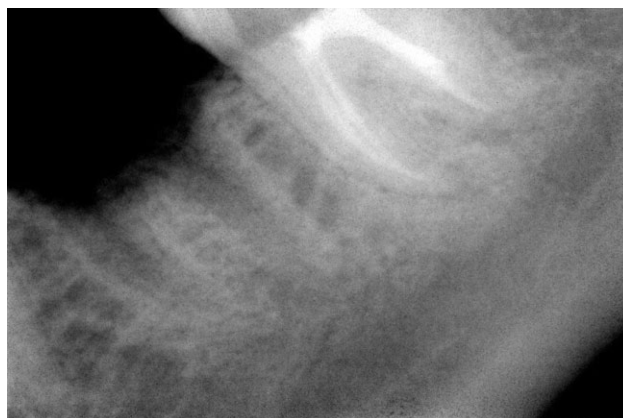


Figure 3 Preoperative view of the edentulous site. The subject was assessed as having Type 2 bone. An implant osteotomy was prepared under copious external irrigation by sequential cutting with internally irrigated drills in graduated diameters (contributed by Guillermo Pradies, DDS).

accordance with the product's instructions for use (IFU). At the time of implant surgery (Figures 2–6), patients were administered anesthesia and prophylactic antibiotics according to their needs and the preference of the investigator. All TM dental implants used in the study were 4.1, 4.7, or 6.0 mm in diameter and 10, 11.5, or 13 mm in length. Investigators were required by the study protocol to record implant insertion torque and were also encouraged to provide additional diagnostic information, such as resonance frequency analysis (RFA) values. Intraoral radiographs and standardized periapical radiographs (XCP, Rinn Dentsply, York, PA, USA) were taken at surgery and annual monitoring appointments. After surgery, decisions regarding the use of prophylactic antibiotics and analgesics, time of suture

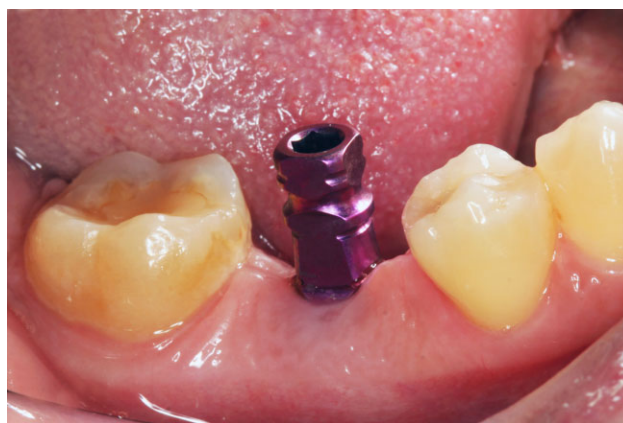

Figure 4 Buccal view of the implant mount before its removal. The implant was threaded into the prepared receptor site per IFU (contributed by Guillermo Pradies, DDS).

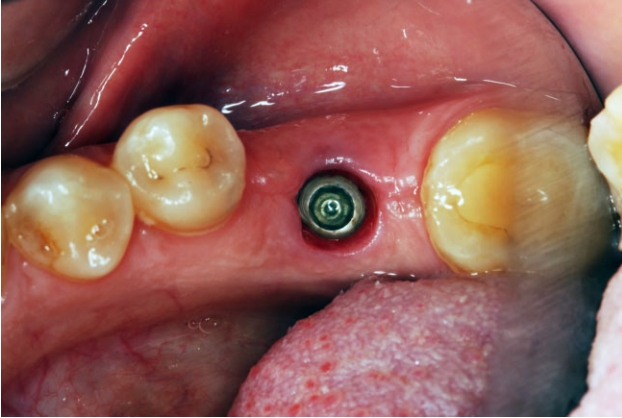

Figure 5 Occlusal view of the implant's internal hexagon connection before attaching the healing collar and suturing the soft tissues around it for nonsubmerged healing (contributed by Guillermo Pradies, DDS).

removal, and the type of implant restoration were left to the investigators based on patient needs.

Monitoring

All treatment timelines were established by the investigators. Osseointegration was determined by clinical and radiographic examinations, which included attempted gentle torquing and manual palpation prior to determine implant stability prior to prosthetic loading, and an absence of irresolvable clinical symptoms, such as pain or suppuration, with or without the presence of peri-implant radiolucency on periapical radiographs. Crestal bone loss was summarized as the mean of radiographic mesial and distal changes in bone height from the time of placement to the 1-year evaluation (Figures 7 and 8).

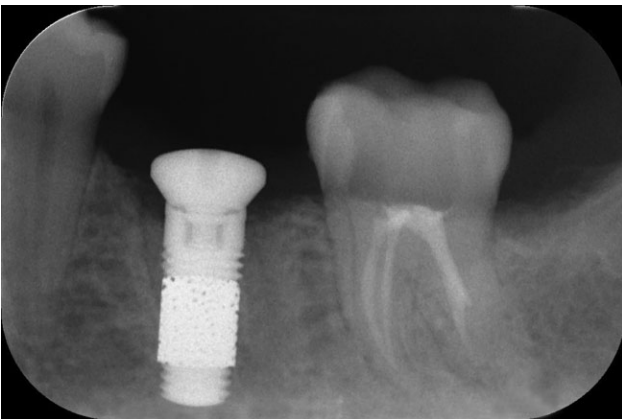


Figure 6 Postoperative radiograph of the implant and titanium healing collar in place (contributed by Guillermo Pradies, DDS).

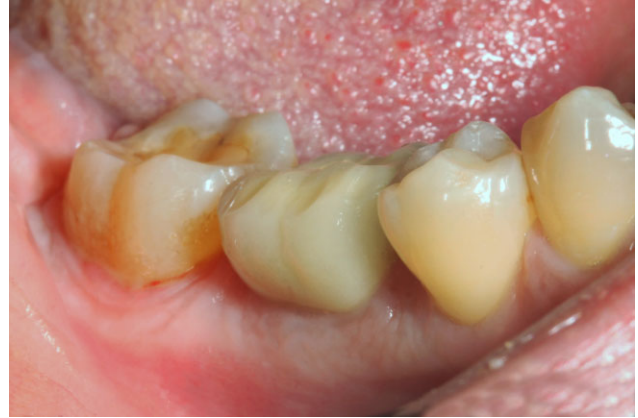

Figure 7 After healing, the implant was uncovered and provisionalized. The definitive restoration was delivered after soft tissue maturation (contributed by Guillermo Pradies, DDS).

Statistical Analysis

Continuous data were summarized by descriptive statistics of group size N , average, standard deviation, median, and range. Categorical data were summarized by descriptive statistics of frequency and percentage. All analyses were performed on a personal computer with a statistical software (SAS 9.2 TS LEVEL 1M0 XP PRO PLATFORM, SAS Institute Inc., Cary, NC, USA).

RESULTS

The initial interim focus group consisted of 116 subjects treated with 160 implants. From this group, 11 patients with 15 implants were subsequently excluded for IFU contraindications (heavy smokers >140 cigarettes/week, alcoholic and substance abuse, uncontrolled systemic

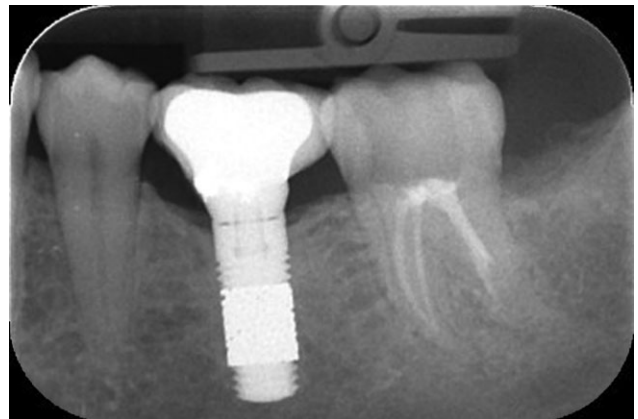


Figure 8 After 1-year of functional loading, there was a mean bone gain of 0.34 mm (0.51 mm mesial, 0.17 mm distal) (contributed by Guillermo Pradies, DDS).

conditions), protocol violations, and iatrogenic surgical errors (Table 2). The final interim focus group consisted of 145 implants placed in 105 subjects (50 men, 55 women) with a mean age of 55.2 ± 11.7 (range = 22–77) years. Within this group, 26.7% ($n = 28$) of the subjects with 43 implants had concomitant health conditions: smoking ($n = 17$), history of periodontitis ($n = 11$), history of osteoporosis ($n = 2$), history of bruxism or tooth clenching ($n = 4$), history of myocardial infarction or cardiac disease ($n = 4$), and intraoral infection that affected the implant site ($n = 1$). Eight (28.6%) of these subjects had two or more concomitant health conditions. One subject had a history of implant failure near the treatment site.

Treatment data are summarized in Table 3. Patients were treated with 145 (mandibular = 88, maxillary = 57) dental implants placed in molar (mandibular = 78; maxillary = 45) or premolar (mandibular = 10; maxillary = 12) locations. The majority of implants ($n = 111$, 76.6%) were placed in patients with a thick soft tissue biotype, and the remaining 34 (23.5%) implants were placed in patients with a thin tissue biotype. Because of ridge deficiencies, simultaneous bone grafting was performed during placement of 43 (29.7%) implants, and 18 (12.4%) implants were placed in previously augmented sites. A total of 16 implants (11.0%) were immediately placed in tooth extraction sockets, 12 of which required simultaneous guided bone regeneration to address buccal dehiscence defects. At least 11 (8.6%) implants were placed in grafted sinuses.

During surgery, clinicians were asked to report the patient's bone density using the Lekholm-Zarb³⁹ scale.

Assessments were based on tactile feedback during drilling, and the investigator's analysis of computed tomography scans was taken during initial patient evaluations. Of the 145 implants placed, implant stability was assessed either by tactile feedback ($n = 135$; 93.1%), RFA ($n = 6$; 4.1%), or a combination of RFA and tactile feedback ($n = 1$; 0.7%). Most implant sites were reported to consist of type 2 bone ($n = 63$; 43.5%), followed by type 3 ($n = 48$; 33.1%), type 4 ($n = 18$; 12.4%), and type 1 ($n = 16$; 11.0%) bone, respectively. When placing the study implant in type 4 bone (soft bone), an osteocompressive surgical technique was recommended by the manufacturer but was not specified by the IFU. This was accomplished by ending the preparation of the implant osteotomy with an intermediate drill and allowing the tapered implant to compress or condense the walls of the osteotomy as the implant was placed. There were 45 cases wherein the soft bone surgical protocol was used in type 3 ($n = 32$, 22.1%), type 2 ($n = 12$; 8.3%), and type 1 ($n = 1$; 0.7%) bone. All implants were still able to be completely seated despite the underprepared osteotomies. Correct use of the osteocompressive or soft bone surgical technique was reported for 18 (12.4%) implants placed in type 4 bone. Study implants were restored with fixed partial dentures, removable partial dentures, or single-tooth restorations.

There were 10 reported nonfailure-related adverse events (Table 4). Radiographic evaluations of six implants in five subjects showed peri-implant radiolucency at the 6-month monitoring appointment. All six implants, which had been placed into fresh sinus grafts, were clinically functioning without any clinical symptoms of failure, such as pain, suppuration, or implant mobility. At the 1-year follow-up, the peri-implant radiolucency had completely resolved around all six implants. In one additional patient, peri-implant radiolucency was not observed around the implant until the 1-year follow-up; however, the implant has continued to function with no adverse clinical symptoms and is being closely monitored. One screw-retained, single-tooth restoration loosened in one subject at the 1-year follow-up and was retightened. In another patient, two prosthetic screws retaining a fixed partial denture loosened at 6 months and again at the 1-year follow-up. The prosthesis retention screws were retightened at both appointments, and the patient continues to be monitored.

A total of seven implants failed in six subjects: three implants in three subjects were explanted and listed as

TABLE 2 Reasons for Exclusions

Reason for Exclusion	Patients (n)	Implants (n)
IFU contraindications		
Smoking more than 140 cigarettes per week	3	4
Uncontrolled systemic conditions (diabetes)	1	2
Alcoholism, other substance abuse, or mental instability	2	4
Protocol contraindication	1	1
Iatrogenic surgical errors	4	4
Total exclusions	11	15

IFU, instructions for use.

TABLE 3 Distribution of Treatment by Implant Placement		n (%)
Implant data	Implant length	10 mm long = 79 (54.5)
		11.5 mm long = 52 (35.9)
		13 mm long = 14 (9.6)
	Implant diameter	4.7 mm = 125 (86.2)
		6.0 mm = 20 (13.8)
	Collar design	Machined = 83 (57)
		Textured = 62 (43)
Placement data	Mandibular jaw	All = 88 (60.7)
		Molar = 78 (53.8)
		Premolar = 10 (6.9)
	Maxillary jaw	All = 57 (39.3)
		Molar = 45 (31.0)
		Premolar = 12 (8.3)
	Time of placement	Fresh extraction socket = 16 (11.0)
		Healed extraction site = 129 (89.0)
	Maximum insertion torque	10–19 Ncm = 7 (4.8)
		20–29 Ncm = 26 (17.9)
		30–44 Ncm = 57 (39.3)
		45–59 Ncm = 45 (31.1)
		60 Ncm = 10 (6.9)
Soft tissue biotype	Thick = 112 (77.24)	
	Thin = 44 (22.76)	
Smoking	Nonsmokers = 125 (86.21)	
	Smokers = 20 (13.79)	
Surgical protocol	One-stage = 90 (62.1)	
	Two-stage = 55 (37.9)	
Bone type	Type 1 = 16 (11.0)	
	Type 2 = 63 (43.5)	
	Type 3 = 48 (33.1)	
	Type 4 = 18 (12.4)	
Insertion protocol	Standard = 82 (56.6)	
	Osteocompressive = 63 (43.4)	
Vertical positioning	Supracrestal = 11 (7.6)	
	Crestal = 108 (74.5)	
	Subcrestal = 26 (17.9)	
Bone graft data	Distribution by implant site	Bone grafts = 62 (42.8)
		No bone grafts = 83 (57.2)
	Time of grafting	Before implant surgery = 18 (29.1)
		Simultaneous with implant surgery = 44 (70.9)
Type of materials*	Xenograft = 34 (54.8)	
	Autograft = 13 (21.0)	
	Allograft = 6 (9.7)	
	Mixture of more than one graft types = 4 (6.5)	
	Alloplast = 4 (6.5)	

*1 implant placed in prior grafted site has no info on graft type.

TABLE 4 Summary of Nonfailure-Related Adverse Events

Location				
Quadrant	Tooth	Problem	Treatment	Outcome
Implant-Related Adverse Events				
Maxillary left	First molar	Peri-implant radiolucency*	Monitoring	Unresolved†
Mandibular left	Second molar	Peri-implant radiolucency‡	Monitored	Resolved
Maxillary right	First molar	Peri-implant radiolucency‡	Monitored	Resolved
Maxillary left	First molar	Peri-implant radiolucency‡	Monitored	Resolved
Maxillary right	First molar	Peri-implant radiolucency‡	Monitored	Resolved
Mandibular right	First molar	Peri-implant radiolucency‡	Monitored	Resolved
Mandibular left	First molar	Peri-implant radiolucency‡	Monitored	Resolved
Prosthesis-Related Adverse Events				
Maxillary right	First molar	Loose prosthesis	Retightened	Resolved
Mandibular left	Second premolar	Loose prosthesis	Retightened	Resolved
Mandibular right	Second molar	Loose prosthesis	Retightened	Resolved

*Observed radiographically at 1 year with no implant mobility, suppuration, or pain.

†Implant is still functioning without clinical symptoms and is being closely monitored.

‡Observed radiographically at 6 months with no implant mobility, suppuration, or pain.

failures due to local or systemic infection (Table 5). The remaining four implant failures in three subjects failed to integrate and were explanted (Table 5). The patients were successfully retreated outside of the study. Based on the seven failures to date, the cumulative interim implant survival rate for all implants placed during the developmental period was 95.2% ($n = 138/145$) after 1 year of clinical monitoring. Gingival health⁴⁰ and plaque⁴¹ indices were recorded at all monitoring appointments (Table 6). After 1 year of clinical func-

tioning, 90.8% ($n = 99$) of the implants had no gingival inflammation, and 78.0% ($n = 85$) had no plaque; however, each of these values represented a slight increase in mild gingivitis and light plaque scores recorded at the 6-month follow-up (Table 6).

Cumulative peri-implant marginal bone loss (mesial and distal sites combined) for 115 implants was 0.43 ± 0.57 1 year after placement (Table 7). It is important to note that 17 subjects who smoked less than 140 cigarettes per week were included in this uncontrolled

TABLE 5 Summary of Failures

Location					
Quadrant	Tooth	Nature of Complication	Cause	Potential Risk Factors*	Time to Failure (weeks)
Maxillary right	Second premolar	Failure to integrate	Unknown	Smoker†	12
Maxillary left	Second premolar	Failure to integrate	Unknown		
Maxillary right	Second molar	Failure to integrate	Patient induced‡	None	16
Mandibular right	Second molar	Failure to integrate	Infection	None	23
Mandibular left	First molar	Infection	Unknown	None	31
Maxillary right	First molar	Infection	Systemic	Multiple§	22
Maxillary right	First premolar	Infection	Unknown	Multiple¶	4

*Assessment per case report forms.

†Patient was a smoker (40 cigarettes per week).

‡Patient chewed ice cubes during implant healing.

§Type 4 bone, grafted sinus, infection started with sinusitis.

¶Smoker, lost implant after hospitalization.

TABLE 6 Periodontal Health

Index	Value	6 Months		1 Year	
		<i>n</i>	%	<i>n</i>	%
Gingival health	0 = No inflammation	109	91.59	99	90.82
	1 = Mild gingivitis	8	6.72	9	8.25
	2 = Gingivitis	2	1.68	1	0.91
Plaque accumulation	0 = No plaque	96	80.67	85	77.98
	1 = Light plaque	18	15.12	22	20.18
	2 = Moderate plaque	5	4.21	2	1.83

population (Table 2). Mean crestal bone loss among smokers ($n = 15$ subjects, 20 implants) was 0.5353 ± 0.6833 mm as compared with 0.4226 ± 0.5605 mm for nonsmokers ($n = 90$ subjects, 125 implants) ($p = .1955$) (Table 7). By soft tissue biotype, mean crestal bone loss was 0.4016 ± 0.5893 mm for thick tissue ($n = 81$ subjects, 112 implants) as compared with 0.5652 ± 0.4872 mm for thin tissue ($n = 24$ subjects, 33 implants) ($p = .2215$) (Table 7). By implant neck design (Figure 1), mean crestal bone loss was 0.4074 ± 0.5350 mm for implants with 0.5 mm of machined implant necks ($n = 62$ subjects, 83 implants) as compared with 0.4762 ± 0.6295 mm for implant with fully textured cervical regions ($n = 43$ subjects, 62 implants) ($p = .5315$) (Table 7).

DISCUSSION

The present noninterventional study is being conducted in an uncontrolled population. The purpose of this

study design is to minimize the manufacturer bias and provide results that reflect outcomes achievable in actual dental practices. Consequently, this interim report includes a large number of patients (26.7%; $n = 28$) with concomitant health conditions. Within this group, the most frequent risk factor for crestal bone loss and implant failure was smoking ($n = 17$; 11.7%), which was also reported in combination with other health risk factors in several patients. Despite over two decades of research on the effects of smoking on dental implants, controversy still persists. Some meta-analyses⁴² and systematic reviews⁴³ have reported that smoking enhanced risks of biologic complications, such as peri-implantitis and implant failure, while individual studies have reported that smoking had no significant impact on the prognosis of implants with grit-blasted, acid-etched, or anodic oxidized surfaces.⁴² In addition, definitions of what constitutes “light” smoking from “heavy” smoking remain inconsistent, and it is still unknown if the risks of

TABLE 7 Implant-Level Cumulative Marginal Bone Loss at 1 Year (mm)

Category	Variable	<i>n</i>	Mean \pm SD	<i>p</i> Value*
All implants	Mesial bone change	105	0.45 ± 0.60	N/A
	Distal bone change	105	0.42 ± 0.68	N/A
	Cumulative bone change	105	0.43 ± 0.57	N/A
Type of cervical microtexture	Microtextured [†]	62	0.4762 ± 0.6295	.5315 [‡]
	Machined*	83	0.4074 ± 0.5350	
Implants placed in smokers	Nonsmokers	103	0.4226 ± 0.5605	.1955 [§]
	Smokers	12	0.5353 ± 0.6833	
Soft tissue biotype	Thick	92	0.4016 ± 0.5893	.2215 [‡]
	Thin	23	0.5652 ± 0.4872	

*Microtextured = microtextured surface extends to the top of the implant’s cervical region.

[†]Machined = 0.5 mm of machined titanium surface intervenes between the microtextured surface and the top of the implant’s cervical region.

[‡]*t*-Test.

[§]Wilcoxon Rank Sum Test.

N/A, not applicable; SD, standard deviation.

crestal bone loss and implant failure can be mitigated by decreasing the amount of smoking that a patient does. In a recent analysis that aimed to identify predictors of implant failure and peri-implant bone loss, Vervaeke and colleagues⁴⁴ reported that smoking was the most identified predictor of both adverse outcomes.

In the present interim analysis, 10 (6.9%) of the subjects had a history of periodontitis but did not have active infections at the time of implant placement. Although a history of periodontitis does not appear to adversely affect implant survival in itself, research has suggested that patients with a history of the disease may have an increased risk of peri-implant bone loss⁴⁵ and/or of developing peri-implantitis⁴⁶ over time. The degree of risk significantly increases if the periodontitis patient also smokes.⁴³ If left untreated, progressive bone loss can ultimately result in component fracture and/or implant failure.

One patient in the focus group had osteoporosis, a condition characterized by poor bone density, bone resorption, and bone fracture in areas of the skeletal system that are affected; however, other sites remote to the diseased tissue in the same skeletal system can remain unaffected.⁴⁷ In such cases, implant placement in the edentulous jaws of osteoporotic patients has been reported to provide beneficial mechanical stimulation to help prevent further resorption of the jawbone, provided there was adequate bone volume and density to support the implants.⁴⁸ Other studies, however, have found correlations between systemic and oral bone mineral densities and that osteoporosis was a risk factor for the progression of periodontal disease.⁴⁹

Three study subjects were reported to have bruxism, which is defined as “a stereotyped movement disorder characterized by grinding or clenching of the teeth during sleep.”^{50–51} Because nocturnal bite force during bruxism can exceed the amplitude of maximum voluntary bite force during daytime,⁵² there is a clinical concern that subjecting dental implants to bending overload during periods of bruxing can ultimately result in a sequelae of crestal bone loss, propagation of fatigue striations in the implant metals, and ultimate fatigue fracture of the implant system.⁵³ Other researchers,⁵⁴ however, have stated that evidence of a causal relationship between bruxism and implant failure has yet been demonstrated. Methods to prevent overloading of implants in bruxers include avoiding implant placement

in the posterior jaw, reducing occlusal contacts, and using an occlusal night guard.^{53,54}

Four study subjects had a history of myocardial infarction or cardiac disease, both of which have been correlated with increased susceptibility to periodontitis, chronic inflammation, and poor oral health.^{55,56} While these factors may have a deleterious effect on long-term implant health, they have not been found to adversely impact the patient’s ability to achieve osseointegration.⁵⁷ In extreme cases, poor cardiac health may impact a patient’s ability to undergo some surgical procedures, and in such cases, consultation with the patient’s physician is highly recommended before implant surgery.

One patient had a history of infection that affected the implant site, but the infection was resolved and there was no clinical evidence that it posed a risk factor for implant survival. Another patient had a history of implant failure near the treatment site. The failure of osseointegrated implants has been described as a complex, multifactorial process that cannot always be attributed to clinical factors alone.⁵⁷ While some research⁵⁸ in the dental literature has suggested a possible genetic predisposition for implant failure, there is currently no evidence to suggest that the past implant failure in this patient could be attributed to anything more than clinical factors. The remaining six patients in this interim focus group had two or more concomitant health conditions, which may compound their risks for long-term bone loss and/or implant survival.

Bone density was assessed by tactile feedback alone while preparing implant osteotomies in 93.1% ($n = 135$) of the study sites. In an unrelated study,⁵⁹ subjective assessments of bone density based on tactile feedback during drilling were correlated with histological analyses of the same bone sites. The researchers⁵⁹ found that clinicians could accurately identify hard (type 1) and soft (type 4) bone but could not accurately identify the intermediate (types 2 and 3) bone densities. Consequently, assessment of bone density only by tactile feedback in the present study should be viewed with caution.

Despite the ability to accurately detect soft (type 4) bone via tactile feedback during osteotomy preparation,⁵⁹ the soft bone surgical protocol was used in 45 implant sites with reportedly greater bone density. Placing a tapered implant into a slightly underprepared osteotomy has been advocated to improve primary

stability in soft bone, but the technique may lead to high compression forces and elevated insertion torque values in bone with greater density.⁶⁰ Concerns have been raised that such cases may impair local microcirculation, cause osteocyte necrosis, and result in bone resorption.⁶⁰ One study,⁶⁰ however, investigated implants placed at high insertion torques up to 176 Ncm and found that it did not impair osseointegration or lead to greater bone loss than control implants that were placed at lower torque with a nonosteocompressive technique. Additional research is needed to better understand the benefits and risks of osteocompressive surgical techniques in dense and moderately dense bone.

At the 1-year follow-up, one study implant had peri-implant radiolucency without any adverse clinical symptoms, such as pain, suppuration, or mobility. It is unknown if the peri-implant radiolucency was present but not observed in earlier radiographs or if the radiolucency developed after the 6-month monitoring appointment. The implant continues to function without symptoms of clinical failure, however, and is being closely monitored for future changes.

Implants in this interim analysis achieved 95.2% survival in the uncontrolled patient population. While all implants were placed by surgeons well experienced in placing multiple implant systems, none had prior experience in placing the study device. Although some surgical errors may have been made as part of a clinical learning curve, none was beyond what any other experienced clinician might experience in placing an unfamiliar device. These outcomes represent the earliest clinical evaluations of TM dental implants, which occurred during the development period of 2010 to 2011. Outcomes from this development period will be compared with implants placed during the postdevelopment period in future reports from this prospective study.

CONCLUSIONS

Interim study findings indicated that TM dental implants were clinically effective under various clinical conditions in an uncontrolled cross section of patients with and without concomitant health conditions.

DISCLOSURE

This study was funded by Zimmer Dental Inc., Carlsbad, CA, USA.

REFERENCES

1. Bothe RT, Beaton LE, Davenport HA. Reaction of bone to multiple metallic implants. *Surg Gynec Obstet* 1940; 71:598–602.
2. Leventhal GS. Titanium, a metal for surgery. *J Bone Joint Surg Am* 1951; 33:473–474.
3. Brånemark P-I, Adell R, Briene U, Lindström J, Hallén O, Öhman A. Osseointegrated implants in the treatment of the edentulous jaw. Experience from a 10-year period. *Scand J Plast Reconstr Surg* 1977; 111(Suppl 16):1–132.
4. Albrektsson T. Hard tissue implant interface. *Aust Dent J* 2008; 53(Suppl 1):S34–S38.
5. Lian Z, Guan H, Ivanovski S, Loo YC, Johnson NW, Zhang H. Effect of bone to implant contact percentage on bone remodeling surrounding a dental implant. *Int J Oral Maxillofac Surg* 2010; 39:690–698.
6. Brånemark P-I. Introduction to osseointegration. Chapter 1. In: Brånemark P-I, Zarb GA, Albrektsson T, eds. *Tissue-integrated prostheses. Osseointegration in clinical dentistry*. Chicago: Quintessence Publishing Co, 1985:11–76.
7. Albrektsson T. Bone tissue response. Chapter 6. In: Brånemark P-I, Zarb GA, Albrektsson T, eds. *Tissue-integrated prostheses. Osseointegration in clinical dentistry*. Chicago: Quintessence Publishing Co, 1985: 129–143.
8. Roberts EW, Poon LC, Smith RK. Interface of rigid endosseous implants. *J Oral Implantol* 1986; 12:406–416.
9. McMillan PJ, Riggs ML, Bogle GC, Crigger M. Variables that influence the relationship between osseointegration and bone adjacent to an implant. *Int J Oral Maxillofac Implants* 2000; 15:654–661.
10. Liu X, Lim JY, Donahue HJ, Dhurgati R, Mastro AM, Vogler EA. Influence of substratum surface chemistry/energy and topography on the human fetal osteoblastic cell line hFOB 1.19: phenotypic and genotypic responses observed in vitro. *Biomaterials* 2007; 28:4535–4550.
11. Vandamme K, Naert I, Sloten JV, Puers R, Duyck J. Effect of implant surface roughness and loading on peri-implant bone formation. *J Periodontol* 2008; 79:150–157.
12. Spector M. Historical review of porous-coated implants. *J Arthroplasty* 1987; 2:163–177.
13. Brentel AS, Vasconcellos LMR, Oliveira MV, et al. Histomorphometric analysis of pure titanium implants with porous surface versus rough surface. *J Appl Oral Sci* 2006; 14:213–218.
14. Hulbert SF, Cooke FW, Klawitter JJ, et al. Attachment of prostheses to the musculoskeletal system by tissue ingrowth and mechanical interlocking. *J Biomed Mater Res* 1973; 7:1–23.
15. Bobynd JD, Pilliar RM, Cameron HU, Weatherly GC. The optimum pore size for the fixation of porous-surfaced metal implants by the ingrowth of bone. *Clin Orthop Relat Res* 1980; 150:263–270.

16. Karageorgiou V, Kaplan D. Porosity of 3D biomaterial scaffolds and osteogenesis. *Biomaterials* 2005; 26:5474–5491.
17. Hacking SA, Bobyn JD, Toh KK, Tanzer M, Krygier JJ. Fibrous tissue ingrowth and attachment to porous tantalum. *J Biomed Mater Res* 2000; 52:631–638.
18. Zardiackas LD, Parsell DE, Dillion LD, Mitchell DW, Nunnery LA, Poggie R. Structure, metallurgy, and mechanical properties of a porous tantalum foam. *J Biomed Mater Res* 2001; 58:180–187.
19. Wigfield C, Robertson J, Gill S, Nelson R. Clinical experience with porous tantalum cervical interbody implants in a prospective randomized controlled trial. *Br J Neurosurg* 2003; 17:418–425.
20. Nasser S, Poggie RA. Revision and salvage patellar arthroplasty using a porous tantalum implant. *J Arthroplasty* 2004; 19:562–572.
21. Bobyn JD, Poggie RA, Krygier JJ, et al. Clinical validation of a structural porous tantalum biomaterial for adult reconstruction. *J Bone Joint Surg Am* 2004; 86-A:123–129.
22. Shimko DA, Shimko VF, Sander EA, Dickson KF, Nauman EA. Effect of porosity on the fluid flow characteristics and mechanical properties of tantalum scaffolds. *J Biomed Mater Res B Appl Biomater* 2005; 73:315–325.
23. Tsao AK, Roberson JR, Christie MJ, et al. Biomechanical and clinical evaluations of a porous tantalum implant for the treatment of early-stage osteonecrosis. *J Bone Joint Surg* 2005; 87:22–27.
24. Unger AS, Lewis RJ, Gruen T. Evaluation of a porous tantalum uncemented acetabular cup in revision total hip arthroplasty. Clinical and radiological results of 60 hips. *J Arthroplasty* 2005; 20:1002–1009.
25. Levine BR, Sporer S, Poggie RA, Della Valle CJ, Jacobs JJ. Experimental and clinical performance of porous tantalum in orthopedic surgery. *Biomaterials* 2006; 27:4671–4681.
26. Gruen TA, Poggie RA, Lewallen DF, et al. Radiographic evaluation of a monoblock acetabular component. *J Arthroplasty* 2005; 20:369–378.
27. Bencharit S, Byrd WC, Altarawneh S, et al. Development and applications of porous tantalum Trabecular Metal-enhanced titanium dental implants. *Clin Implant Dent Relat Res* 2013; doi: 10.1111/cid.12059.
28. Mazor Z, Cohen DK. Preliminary 3-dimensional surface texture measurement and early loading results with a microtextured implant surface. *Int J Oral Maxillofac Implants* 2003; 18:729–738.
29. Chehroudi B, Gould TR, Brunette DM. Effects of a grooved epoxy substratum on epithelial cell behavior *in vitro* and *in vivo*. *J Biomed Mater Res* 1988; 22:459–473.
30. Chehroudi B, Gould TR, Brunette DM. Effects of a titanium-coated implant surfaces on epithelial cell behavior *in vitro* and *in vivo*. *J Biomed Mater Res* 1989; 23:1067–1085.
31. Chehroudi B, Gould TR, Brunette DM. Titanium-coated micromachined grooves of different dimensions affect epithelial and connective-tissue cells differently *in vivo*. *J Biomed Mater Res* 1990; 24:1203–1219.
32. Hall J, Miranda-Burgos P, Sennerby L. Stimulation of directed bone growth at oxidized titanium implants by macroscopic grooves: an *in vivo* study. *Clin Implant Dent Relat Res* 2005; 7:S76–S82.
33. Den Hartog L, Meijer HJA, Tymstra N, Vissink A, Raghoobar GM. Single implants with different neck designs in the aesthetic zone: a randomized clinical trial. *Clin Oral Implants Res* 2011; 22:1289–1297.
34. Zitzmann NU, Abrahamsson I, Berglundh T, Lindhe J. Soft tissue reactions to plaque formation at implant abutments with different surface topography. An experimental study in dogs. *J Clin Periodontol* 2002; 29:456–461.
35. Grenoble DE, Voss R. Analysis of five years of study of vitreous carbon endosseous implants in humans. *Oral Implants* 1977; 6:509–525.
36. Grundschober F, Kellner G, Eschberger J, Plenck H Jr. Long term osseous anchorage of endosseous dental implants made of tantalum and titanium. In: Winter GB, Gibbons DF, Plenck H Jr, eds. *Biomaterials* 1980. Chichester: John Wiley & Sons, 1982:365–370.
37. Matsuno H, Yokoyama A, Watari F, Uo M, Kawasaki T. Biocompatibility and osteogenesis of refractory metal implants, titanium, hafnium, niobium, tantalum and rhenium. *Biomaterials* 2001; 22:1253–1262.
38. Schlee M, van der Schoor WP, van der Schoor ARM. Immediate loading of Trabecular Metal-enhanced titanium dental implants: interim results from an international proof-of-principle study. *Clin Implant Dent Relat Res* 2013; doi: 10.1111/cid.12127.
39. Lekholm U, Zarb GA. Patient selection and preparation. In: Brånemark P-I, Zarb GA, Albrektsson T, eds. *Tissue-integrated prostheses. Osseointegration in clinical dentistry*. Chicago: Quintessence Publishing Co, Inc., 1985:199–209.
40. Løe H, Silness J. Periodontal disease in pregnancy. I. Prevalence and severity. *Acta Odontol Scand* 1963; 21:533–551.
41. Silness J, Løe H. Periodontal disease in pregnancy. II. Correlation between oral hygiene and periodontal condition. *Acta Odontol Scand* 1964; 22:121–135.
42. Strietzel FP, Reichart PA, Kale A, Kulkarni M, Wegner B, Kuchler I. Smoking interferes with the prognosis of dental implant treatment: a systematic review and meta-analysis. *J Clin Periodontol* 2007; 34:523–544.
43. Heitz-Mayfield LJA, Huynh-Ba G. History of treated periodontitis and smoking as risks for implant therapy. *Int J Oral Maxillofac Implants* 2009; 24(Suppl):39–68.
44. Vervaeke S, Collaert B, Cosyn J, Deschepper E, De Bruyn H. A multifactorial analysis to identify predictors of implant failure and peri-implant bone loss. *Clin Implant Dent Relat Res* 2013; doi: 10.1111/cid.12149.

45. Ormianer Z, Palti A. The use of tapered implants in the maxillae of periodontally susceptible patients: 10-year outcomes. *Int J Oral Maxillofac Implants* 2012; 27:442–448.
46. Cochran DL, Schou S, Heitz-Mayfield LJA, Bornstein MM, Salvi GE, Martin WC. Consensus statements and recommended clinical procedures regarding risk factors in implant therapy. *Int J Oral Maxillofac Implants* 2009; 24(Suppl):86–89.
47. Dao TTT, Anderson JD, Zarb GA. Is osteoporosis a risk factor of osseointegration of dental implants? *Int J Oral Maxillofac Implants* 1993; 8:137–144.
48. Bianchi A, Sanfilippo F. Osteoporosis: the effect on mandibular bone resorption and therapeutic possibilities by means of implant prostheses. *Int J Periodontics Restorative Dent* 2002; 22:231–239.
49. Geurs NC, Lewis CE, Jeffcoat MK. Osteoporosis and periodontal disease progression. *Periodontol 2000* 2003; 32: 105–110.
50. Diagnostic Classification Steering Committee, Thorpy MJ. *International Classification of Sleep Disorders: Diagnostic and Coding Manual*, revised. Rochester, MN: American Sleep Disorders Association, 1997:182–185.
51. Tosun T, Karabuda C, Cuhadaroglu C. Evaluation of sleep bruxism by polysomnographic analysis in patients with dental implants. *Int J Oral Maxillofac Implants* 2003; 18: 286–292.
52. Nishigawa K, Bando E, Nakano M. Quantitative study of bite force during sleep associated bruxism. *J Oral Rehabil* 2001; 28:485–491.
53. Piattelli A, Piattelli M, Scarano A, Montesani L. Light and scanning electron microscope report of four fractured implants. *Int J Oral Maxillofac Implants* 1998; 13:561–564.
54. Lobbezoo F, Brouwers JEIG, Cune MS, Naeije M. Tandheelkundige implantaten bij bruxisten. *Ned Tijdschr Tandheelkd* 2004; 111:85–90.
55. Montebugnoli L, Servidio D, Miaton RA, Prati C, Tricoci P, Melloni C. Poor oral health is associated with coronary heart disease and elevated inflammatory and haemostatic factors. *J Clin Periodontol* 2004; 31:25–29.
56. Renvert S, Ohlsson O, Persson S, Lang NP, Persson GB. Analysis of periodontal risk profiles in adults with or without a history of myocardial infarction. *J Clin Periodontol* 2004; 31:19–24.
57. Khadivi V, Anderson J, Zarb GA. Cardiovascular disease and treatment outcomes with osseointegration surgery. *J Prosthet Dent* 1999; 81:533–536.
58. Alvim-Pereira F, Montes CC, Mira MT, Trevilatto PC. Genetic susceptibility to dental implant failure: a critical review. *Int J Oral Maxillofac Implants* 2008; 23:409–416.
59. Makary C, Rebaudi A, Mokbel N, Naman N. Peak insertion torque correlated to histologically and clinically evaluated bone density. *Implant Dent* 2011; 20:182–191.
60. Khayat PG, Arnal HM, Turbah BI, Sennerby L. Clinical outcome of dental implants placed with high insertion torques (up to 176 Ncm). *Clin Implant Dent Relat Res* 2013; 15:227–233.